

REVIEW ARTICLE

Bilateral Inverted Papilloma of the Paranasal Sinus: Literature Review

¹Juan Ramon Gras-Cabrerizo, ¹Joan R Montserrat-Gili, ¹Albert Pujol Olmo, ²Manuel de Juan
¹Humbert Masegur-Solench

¹Consultant, Department of Otorhinolaryngology, Santa Creu i Sant Pau, Barcelona, Spain

²Consultant, Department of Radiology, Santa Creu i Sant Pau, Barcelona, Spain

Correspondence: Juan Ramon Gras-Cabrerizo, Consultant, Department of Otorhinolaryngology, Santa Creu i Sant Pau, Barcelona Spain, e-mail: jgras@santpau.cat

ABSTRACT

Objective: We describe an unusual case of bilateral nasal inverted papilloma.

Case report: Inverted papilloma is a benign epithelial tumor that frequently occurs unilaterally. We report a 65-year-old male patient with a bilateral inverted papilloma located in the ethmoid and maxillary sinus. Functional endoscopic sinus surgery was performed in order to completely remove both tumors.

Conclusion: We present a rare entity of bilateral independent sinonasal papilloma treated successfully with endoscopic sinus approach.

Keywords: Inverted papilloma, Bilateral, Ethmoid sinus, Maxillary sinus.

INTRODUCTION

Inverted papilloma is a benign tumor that represents between 0 and 5 to 7% of all nasal neoplasms, with an incidence of 1.5 cases per 100,000 persons-year.¹⁻³

Histologically, these tumors show patterns of inversion of epithelial growth without transgression of the basement membrane.

The etiology is unknown. The role of human papilloma virus (HPV) has been advocated. Viral subtypes 6, 11, 16 and 18 were the most frequently found which could be implicated in 33 to 42% of cases of inverted papilloma.^{4,5} The multifocal origin of these tumors and its rate of recurrence, supports its viral etiology as well as the established association with other papillomas in other areas of the body.

The association of malignancy and inverted papilloma is controversial. The review of the literature shows the presence of a metachronous malignant lesion in 1 to 3% of patients and a synchronous lesion in a 7 to 8% of cases.³⁻⁶

There is a male predominance and most of the cases are diagnosed in adult age. The endoscopic exploration usually shows a mass with multiple digitations located in lateral nasal wall. The maxillary sinus is the second most frequent site while the frontal and sphenoid sinuses' primary localization is quite rare. Intracranial presentation is an unusual feature, yet possible, which is usually associated with recurrent disease. The site of intracranial extension in most of the patients is the cribriform plate ethmoid roof area.⁷

The orbit can be displaced laterally but the involvement of orbital structures by the tumor is infrequent.⁸ The papilloma usually grows in one side of the nose and it is essential to do a differential diagnosis with other unilateral lesions, such as sinonasal carcinoma, esthesioneuroblastoma, choanal polyp and other tumors. We present an unusual case of a patient with a bilateral inverted papilloma.

CASE REPORT

A 65-year-old male consulted our department because of unilateral left nasal obstruction and intermittent epistaxis during the last year. He also complained of anosmia and bilateral epiphora for the past 2 years. He did not present visual dysfunction and the ocular motility was normal without proptosis. He did not refer toxic consumption.

Anterior rhinoscopy and nasal endoscopy with 0° and 30° rigid endoscope showed a tumor in the left nasal fossa, involving the lateral nasal wall, including the middle and inferior meatus. A biopsy of this nasal mass was performed and revealed an inverted papilloma.

On the other side, we observed a polypoid mass that seemed to emerge from anterior ethmoid sinus. We did not make a biopsy of this lesion.

Computed tomography demonstrated a bilateral mass occupying both nasal fossae, maxillary and ethmoid sinuses (Figs 1A and B). Magnetic resonance showed a left unilateral mass with intermediate signal intensity occupying

the maxillary sinus, involving the anterior and inferior wall, and the upper surface of the inferior turbinate. In the right fossa, we observed a similar mass limited to the anterior ethmoid without extension into the ethmoid roof neither the maxillary sinus, which was very small. The high signal intensity in the lateral portion of the left maxillary sinus suggested the presence of secretions (Figs 1A and B). Endoscopic endonasal surgery was performed under general anesthesia, using 0°, 30° and 45° rigid endoscopes. Cottonoids soaked with tetracaine and adrenaline were previously placed in both nasal cavities. The mass in the left side was removed carefully verifying the origin in the inferomedial maxillary wall. We also removed the entire inferior turbinate. The ethmoid anterior cells were removed without evidence of invasion.

Complete sphenoidectomy and middle antrostomy were carried out in the right side. We noted the mass was

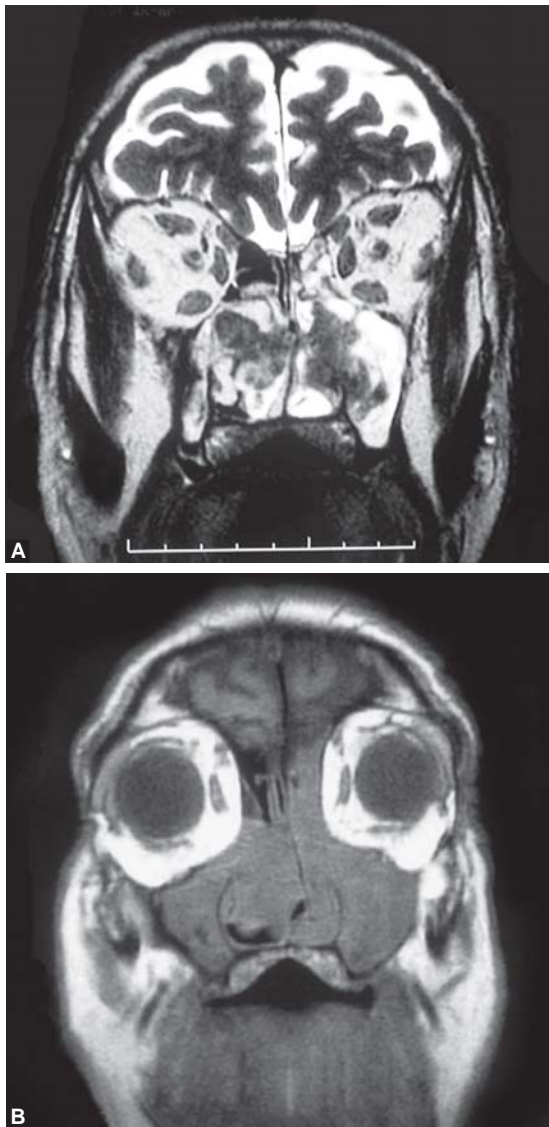
attached to the vertical portion of uncinatus processes and did not involve the maxillary sinus. During the surgery, it was assessed that no communication existed between the right and left side, confirming the bilateral independent lesions.

The postoperative pathologic features were reported as a bilateral nasal inverted papilloma with no signs of malignancy. The nasal cavities were packed for 24 hours without intraoperative or postoperative complications. During the follow-up, no recurrence was observed in the following 18 months (Fig. 2).

DISCUSSION

Inverted papilloma is a locally aggressive benign nasal tumor with a high recurrence tendency. Although lateral rhinotomy or sublabial degloving has been the traditional approach for decades, in the recent literature, an endoscopic approach has been considered, showing similar results than the previous and avoiding the morbidity associated with open approaches. Some of these advantages are the lack of facial incision, decreased crusting, less postoperative pain, decreased postoperative bleeding and less health care costs. The first report on endoscopic treatment of inverted papilloma dates back to 1981 when Stammberger documented 15 patients treated by a purely endoscopic approach.⁹ Since then, numerous authors have reported their experience in the treatment of this lesion by exclusively endoscopic approach showing successful results comparable to external techniques.

The local recurrence after endoscopic resection has been reported by several studies with an average recurrence that ranges from 0 to 24% of the patients who underwent an endoscopic approach.¹⁰⁻¹⁶ Lawson et al¹⁰ employed a



Figs 1A and B: Coronal computed tomography and coronal magnetic resonance demonstrating a left mass occupying the maxillary sinus involving the anteroinferior wall. In the right side, we observe a mass limited to the anterior ethmoid sinus

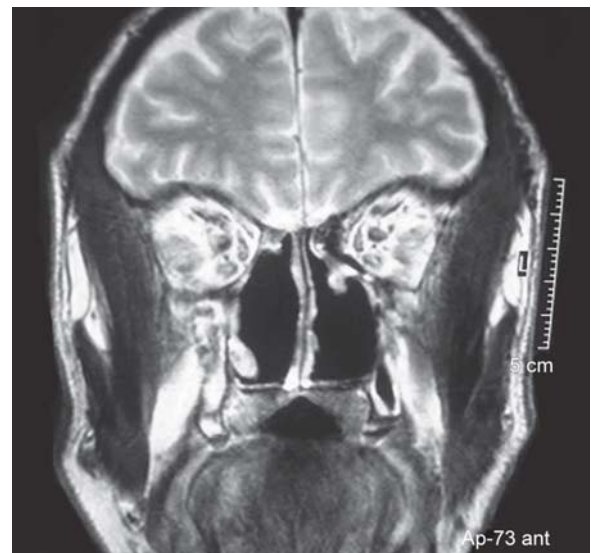

Fig. 2: Postoperative coronal magnetic resonance showing complete removal of the tumors

Caldwell-Luc procedure with endonasal approach for tumors extending to the lateral portion of the maxillary sinus and external frontoethmoidectomy when the tumor extended into the nasofrontal duct, superoethmoid cells, periacrimal cells and orbit. Lane and Bolguer¹⁷ advocate that Caldwell-Luc approach should be used when the tumor involves lateral, inferior or anterior wall of the maxillary sinus.

Pasquini et al¹³ concluded that Krouse system stages T1-T2 and selected T3 cases are suitable for endoscopic resection. Banhiran and Casiano¹⁸ perform a Lothrop procedure in cases of inferomedial wall of frontal sinus invasion and osteoplastic flap in cases of lateral or more superior involvement.

In our center, inverted papillomas are mainly treated with endoscopic approach. We indicate external surgery when the papilloma involves the alveolar recess (Caldwell-Luc procedure or sublabial approach), when the tumor erodes the anterior skull base (craniofacial resection) or when the lesion involves the lateral and superior walls of frontal sinus (osteoplastic procedure or a subciliary incision).

After reviewing the literature, we have only found three cases of noniatrogenic bilateral inverted papilloma.¹⁹⁻²¹

We present a case of a patient with an ethmoid papilloma in the right nasal fossa associated to another inverted papilloma in the left side with an origin in the maxillary sinus.

We decided to perform an endoscopic approach in both fossae but informed the patient about the possibility to extend the surgery with a sublabial incision if the mass in the left side was found to be attached at the alveolar recess. The inferior turbinate was included in the surgical specimen because of the suspicion of its infiltration by papilloma as well as to gain access to the anteromedial maxillary sinus due to the proximity of the lesion. The tumor's surrounding mucosa was completely removed. The ethmoid anterior cells were removed without evidence of invasion.

In the right side, the mass was attached to the lateral wall, at the vertical portion of uncinat process and did not involve the maxillary sinus, thus, performing a complete sphenoidectomy and middle antrostomy. The dissection of the ethmoid sinus was carried out in a subperiosteal plane. The papiracea was not rejected.

During the 18 months follow-up, no recurrence was observed by endoscopic examination. Computed tomography scan and magnetic resonance imaging were performed on the first postoperative year without showing any recurrence.

It is the unique bilateral case in our database of 79 inverted papillomas treated in our center from 1978 to 2008 and it is a rare entity in the literature. There is no doubt that it is an exceptional case that demonstrates that in most of

the cases inverted papilloma is an unilateral lesion but it may occasionally be bilateral.

CONCLUSION

Sinonasal inverted papilloma is a benign epithelial tumor that in most cases occur unilaterally. We present a rare entity of bilateral independent papilloma located in the ethmoid and maxillary sinus respectively. This patient was treated successfully with endoscopic sinus approach.

REFERENCES

1. Buchwald C, Franzmann MB, Tos M. Sinonasal papillomas: A report of 82 cases in Copenhagen County, including a longitudinal epidemiological and clinical study. *Laryngoscope* Jan 1995;105(1):72-79.
2. Outzen KE, Grøntved A, Jørgensen K, Clausen PP, Ladefoged C. Inverted papilloma: Incidence and late results of surgical treatment. *Rhinology* Jun 1996;34(2):114-18.
3. Sauter A, Matharu R, Hörmann K, Naim R. Current advances in the basic research and clinical management of sinonasal inverted papilloma (review). *Oncol Rep* Mar 2007;17(3):495-504.
4. Syrjänen KJ. HPV infections in benign and malignant sinonasal lesions. *J Clin Pathol* Mar 2003;56(3):174-81.
5. Katori H, Nozawa A, Tsukuda M. Markers of malignant transformation of sinonasal inverted papilloma. *Eur J Surg Oncol* Oct 2005;31(8):905-11.
6. Mirza S, Bradley PJ, Acharya A, Stacey M, Jones NS. Sinonasal inverted papillomas: Recurrence and synchronous and metachronous malignancy. *J Laryngol Otol* Sep 2007;121(9):857-64.
7. Vural E, Suen JY, Hanna E. Intracranial extension of inverted papilloma: An unusual and potentially fatal complication. *Head Neck* Dec 1999;21(8):703-06.
8. Bajaj MS, Pushker N. Inverted papilloma invading the orbit. *Orbit* Jun 2002;21(2):155-59.
9. Stammberger H. The inverting papilloma of the nose. *HNO* Apr 1981;29(4):128-33.
10. Lawson W, Kaufman MR, Biller HF. Treatment outcomes in the management of inverted papilloma: An analysis of 160 cases. *Laryngoscope* Sep 2003;113(9):1548-56.
11. Llorente JL, Deleyiannis F, Rodrigo JP, Nuñez F, Ablanedo P, Melón S, et al. Minimally invasive treatment of the nasal inverted papilloma. *Am J Rhinol* Nov-Dec 2003;17(6):335-41.
12. Kraft M, Simmen D, Kaufmann T, Holzmann D. Long-term results of endonasal sinus surgery in sinonasal papillomas. *Laryngoscope* Sep 2003;113(9):1541-47.
13. Pasquini E, Sciarretta V, Farneti G, Modugno GC, Ceroni AR. Inverted papilloma: Report of 89 cases. *Am J Otolaryngol* May-Jun 2004;25(3):178-85.
14. Tomenzoli D, Castelnuovo P, Pagella F, Berlucchi M, Pianta L, Delù G, et al. Different endoscopic surgical strategies in the management of inverted papilloma of the sinonasal tract: Experience with 47 patients. *Laryngoscope* Feb 2004;114(2):193-200.
15. Von Buchwald C, Larsen AS. Endoscopic surgery of inverted papillomas under image guidance: A prospective study of 42 consecutive cases at a Danish university clinic. Von Buchwald C, Larsen AS (Eds). *Otolaryngol Head Neck Surg* Apr 2005;132(4):602-07.

16. Busquets JM, Hwang PH. Endoscopic resection of sinonasal inverted papilloma: A meta-analysis. *Otolaryngol Head Neck Surg* Mar 2006;134(3):476-82.
17. Lane AP, Bolger WE. Endoscopic management of inverted papilloma. *Curr Opin Otolaryngol Head Neck Surg* Feb 2006;14(1):14-18.
18. Banhiran W, Casiano RR. Endoscopic sinus surgery for benign and malignant nasal and sinus neoplasm. *Curr Opin Otolaryngol Head Neck Surg* Feb 2005;13(1):50-54.
19. Chatterji P, Friedmann I, Soni NK, Solanki RL, Ramdeo IN. Bilateral transitional-type inverted papilloma of the nose and paranasal sinuses. *J Laryngol Otol* Mar 1982;96(3):281-87.
20. Hosal SA, Freeman JL. Bilateral lateral rhinotomy for resection of bilateral inverted papilloma. *Otolaryngol Head Neck Surg* Jan 1996;114(1):103-05.
21. Salomone R, Matsuyama C, Giannotti Filho O, Alvarenga ML, Martinez Neto EE, Chaves AG. Bilateral inverted papilloma: Case report and literature review. *Braz J Otorhinolaryngol* Mar-Apr 2008;74(2):293-96.