

Endoscopic medial maxillectomy with preservation of inferior turbinate: how do we do it?

Juan R. Gras-Cabrerizo · Humbert Masegur-Solench ·
Albert Pujol-Olmo · Joan R. Montserrat-Gili ·
Joan M. Ademà-Alcover · Iñaki Zarronandia-Andraca

Received: 2 June 2010 / Accepted: 12 July 2010 / Published online: 27 July 2010
© Springer-Verlag 2010

Abstract The aim of this study was to describe the endoscopic medial maxillectomy technique with preservation of the inferior turbinate in patients affected by maxillary sinonasal inverted papilloma. We retrospectively reviewed the clinical charts and surgical technique in six patients with paranasal sinus inverted papilloma. There were five males and one female, whose mean age at diagnosis was 60 years ranging between 57 and 65 years. No recurrences were diagnosed, and no nasal crusting was evidenced postoperatively. Nasal breathing was satisfying in all cases. Postoperative epistaxis was not observed, and none of the patients referred to have epiphora after the surgery. This technique has been successfully performed, showing no recurrence to the present and allowing the preservation of a functional inferior turbinate.

Keywords Inverted · Papilloma · Medial maxillectomy · Inferior turbinate

Introduction

Inverted papilloma represents almost 70% of all sinonasal papillomas and between 0.5 and 7% of all nasal tumours. It has an incidence of approximately 0.52–1.5 per 100,000 cases a year [1–3].

This benign tumour of epithelial origin has a characteristic histological pattern consisting of endophytic growth of squamous epithelium that penetrates the stroma without

disruption of basement membrane and with a well-known tendency to recur. In recent studies, local recurrence ranges from 0 to 24% [4–10].

For several decades, traditional management when the tumour involved the maxillary sinus was the external approach, lateral rhinotomy or sublabial approach. During the 1990s endonasal transnasal endoscopic medial maxillectomy was advocated by different authors to treat these tumours [11, 13]. Results with the endoscopic technique are satisfactory and comparable to external techniques, and present an aesthetic advantage in avoiding a facial incision as well as a decrease in postoperative issues such as morbidity, crusting, pain, bleeding and health care costs. However, this approach presents the main drawback of sacrificing the inferior turbinate and consequently its critical function in the conditioning of the nasal airflow. The aim of our study was to describe the endoscopic medial maxillectomy with preservation of the inferior turbinate.

Materials and methods

Patients and tumour characteristics

From January 2005 to December 2008, 27 patients with inverted papilloma were treated in our institution. Six of them were tumours that involved the anteromedial wall of the maxillary sinus and were treated with an endoscopic medial maxillectomy conserving the inferior turbinate. All tumours were unilateral. There were five primary lesions, and one patient had been previously treated.

The patients were evaluated preoperatively by nasal endoscopy, CT and MR to assess tumour extension. All patients were classified according to Krouse's staging system [11] and Cannady system [12]. In postoperative

J. R. Gras-Cabrerizo (✉) · H. Masegur-Solench ·
A. Pujol-Olmo · J. R. Montserrat-Gili · J. M. Ademà-Alcover ·
I. Zarronandia-Andraca
Department of Otolaryngology/Head and Neck Surgery,
Hospital de la Santa Creu i Sant Pau,
Universitat Autònoma de Barcelona, Barcelona, Spain
e-mail: Jgras@santpau.cat

Fig. 1 The head of the inferior turbinate is cut, and the suture passes through it

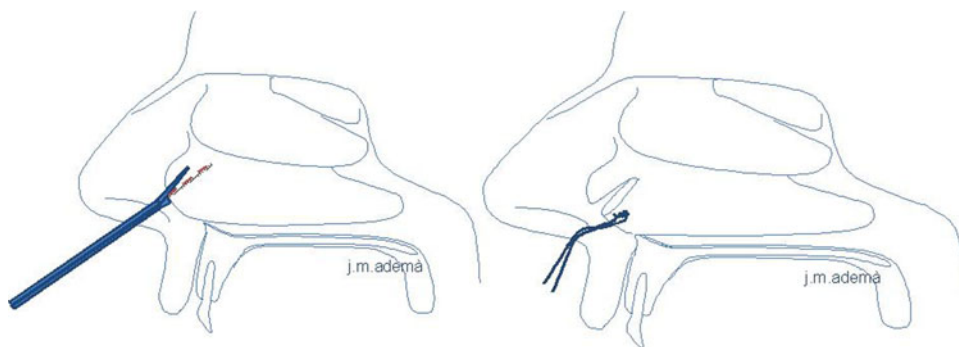
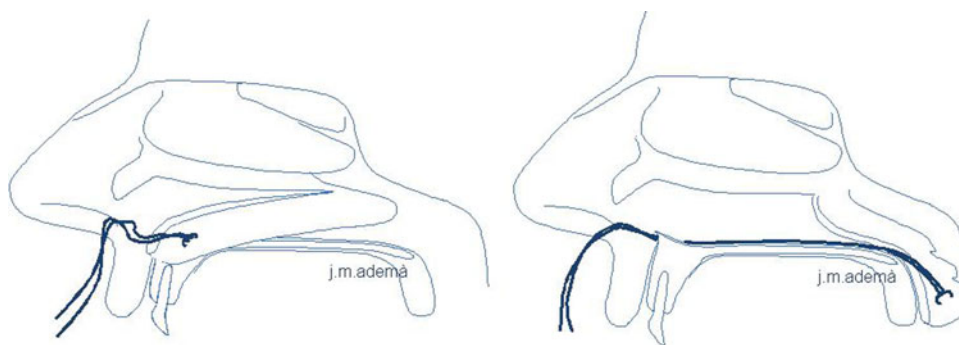


Fig. 2 The rest of turbinate is pediculated to the inferior turbinate artery



controls, we only use imagine exams (CT, MRI) if we observe pathologic findings at the endoscopic examination. The minimum follow-up was 1 year.

Surgical technique

Endoscopic endonasal surgery was performed under general anaesthesia, using 0°, 30° and 45° rigid endoscopes by the two main authors. Cottonoids soaked with tetracaine and adrenaline 1% were previously placed in both nasal cavities. We begin the surgery medially displacing the two anterior thirds of the inferior turbinate with the Freer elevator. In three cases, we previously carried out a partial debulking of the tumour in order to obtain a better visualisation over all the turbinate. We follow by cutting the head of the turbinate with a pair of straight scissors and passed a reabsorbable 3-0 suture through it (Fig. 1). Then we continue by cutting and posteriorly bending the rest of the turbinate until it remains pediculated to the inferior turbinate artery. The curved needle and the final of the suture pass through the floor of the nasal fossa and are fixed with a splint outside the nostril to allow a wider and more comfortable access to the maxillectomy (Fig. 2). The medial maxillary wall is removed including the anterior ethmoid complex, the posterior ethmoid complex or both, according to the tumour extension. The maxillectomy limits are the floor of the nasal fossa, the posterior wall of the maxillary sinus and the anterior wall of the sinus with the nasolacrimal duct anteriorly. A mucosal flap over the frontal process of maxilla is elevated, and the

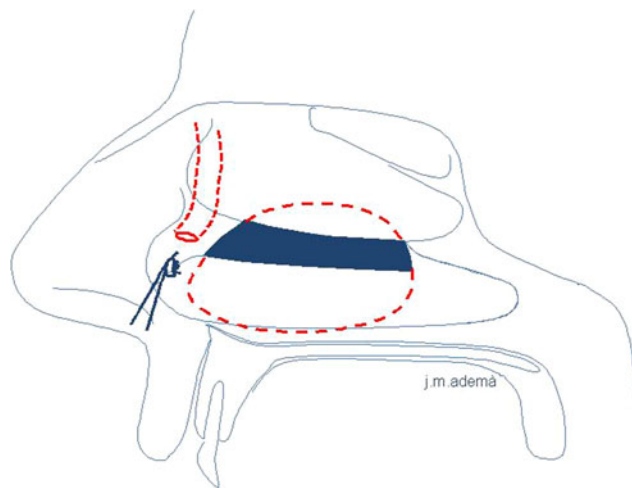


Fig. 3 Medial maxillectomy. The head of the turbinate is closed to the lateral nasal wall

underlying bone is removed to expose the nasolacrimal duct, maintaining its integrity when the tumour does not affect it. The inverted papilloma is resected in a subperiosteal plane. We then pull back the inferior turbinate, sewing back its anterior head to the lateral nasal wall with the previously mentioned needle, and finally closing the suture (Fig. 3). A reabsorbable haemostatic dress is placed covering the head of the turbinate. The nasal cavity is then packed for 24 h, and the patients are discharged home the day after the surgery. A 1-week amoxicillin and clavulanic acid oral antibiotic regime is prescribed followed by nasal irrigations for 1 month.

Results

We performed a medial maxillectomy conserving the inferior turbinate in six patients who underwent the endoscopic procedure. Mean age at diagnosis was 60.7 years with a range between 57 and 65 years. There were five males and one female. Four patients were non-smokers and non-drinkers, and two patients had a mild enolic habit and smoked about 20 cigarettes per day.

While rhinorrhea was observed in only two patients, nasal obstruction was the most frequent symptom, occurring in all patients and referred as being right-sided in four patients and left-sided in the other two patients. None of the patients suffered from epistaxis or facial pain. In all cases the papilloma involved the anteromedial wall of the maxillary sinus (alveolar recess).

According to Krouse's system, all six patients were classified as T3 papillomas. Using the Cannady system, all patients were ascribed to the B stage. No association to paranasal sinus carcinoma was found. Postoperative epistaxis was not observed, and none of the patients referred to have epiphora after the surgery.

Two patients presented numbness in the homolateral superior maxillary bone.

The inferior turbinate remained fixed to the lateral nasal wall with an appropriate size, showing a good level of vascularisation enough to maintain its function in all cases (Fig. 4).

In the fourth week postoperative office control, no nasal crusting was evidenced, and nasal breathing was satisfying in all cases. No recurrences were diagnosed.

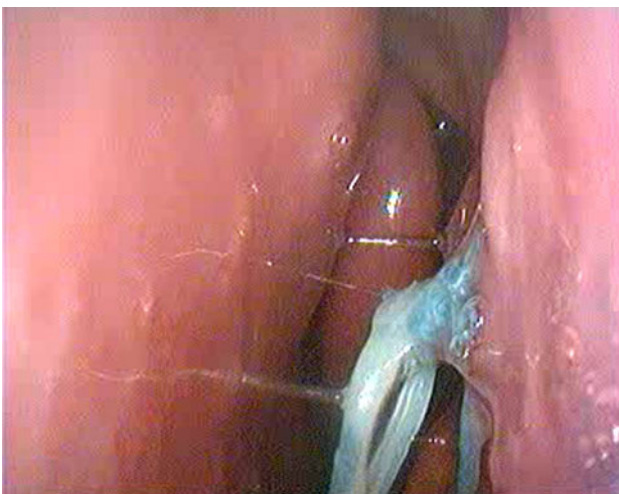

Fig. 4 Three weeks postoperative control

Discussion

Numerous authors have reported their experience with the endonasal endoscopic approach for the treatment of inverted papillomas. When this benign tumour involves the maxillary sinus, most surgeons, in order to avoid the traditional external approach, suggest extended maxillary anrostomies called endoscopic medial maxillectomy [11, 13]. Sadeghi et al. [14] described this technique methodically. They carried out en bloc resection of the entire lateral nasal wall with the tumour. This resection includes the nasolacrimal canal and inferior turbinate with the inferior meatus to gain a good access to the maxillary cavity. The extension of resection is similar to an open medial maxillectomy with a lateral rhinotomy except for the anterior maxillary wall.

In our institution, sinonasal inverted papilloma is nowadays mainly treated with endoscopic surgical resection. When the papilloma involved the anteromedial wall of maxillary sinus or alveolar recess, being it difficult to reach this localisation exclusively by endoscope due to the narrow vision angle, we complemented this approach with the Caldwell-Luc procedure. In the last few years, in order to avoid this sublabial incision, we performed a medial maxillectomy as previously described, preserving since 2005 the inferior turbinate. In the first cases, we replaced the inferior turbinate in the nasal lateral wall with absorbable products. We observed in the postoperative controls that inferior turbinate despite maintaining its vitality, remained in a lower position, even falling off to the ground level of the nasal fossa.

At present, we opt for an endoscopic medial maxillectomy conserving the inferior turbinate but not only repositioning it but also fixing it to the lateral nasal wall with a reabsorbable suture. With this technique, we maintain the whole of the turbinate in its initial position, preserving most of the vascularisation and physiologic function with minimum iatrogenic effects. The inferior turbinate plays an important role in filtering, warming and moistening inspired air, and represents most of the two-thirds of nasal airflow resistance.

There is evidence that radical turbinectomy may result in rhinitis sicca and/or ozaena [15].

These patients feel nasal congestion without having any anatomical obstruction, symptom attributed to the patient's impossibility to recognise the normal nasal sensation of breathing. This is due to the atrophy and or destruction of the trigeminal epithelial receptors, located fundamentally in the head of the inferior turbinate, and due to the lack of nasal resistance (paradoxical obstruction). In those patients who underwent the described technique, we have not found excessive dryness in nasal examination in contrast to those patients in which we performed total turbinectomy. Therefore,

we believe that it is important that the turbinate remains as close to its initial state and position as possible.

One of the limitations of our work is that the functions of the inferior turbinate have not been objectively assessed. Neither rhinomanometry nor acoustic rhinometry was performed in these patients. Although these techniques would help us demonstrate variations in overall nasal flow, other basic functions of the inferior turbinate such as moistening and subjective nasal comfort would not be reflected on them.

Although transoral approaches preserve the inferior turbinate, we believe that the previously mentioned disadvantages retain these techniques as a feasible second choice in front of the endoscopic surgery.

It is shown that total turbinectomy is associated with a significant risk of severe haemorrhage. If inferior turbinate tail is not injured, epistaxis is less likely to occur due to the preservation of inferior turbinate artery. Garth et al. [16] observed postoperative haemorrhage in 0.9% of patients who had anterior turbinectomy and 5.8% in patients who had radical turbinectomy in 214 patients who underwent bilateral turbinate surgery.

We agree with others authors that it is not possible to achieve an appropriate access to the anterior maxillary wall without resecting or mobilising the inferior turbinate. We prefer the resection and repositioning technique to avoid possible iatrogenic effects and complications without penalising the surgical approach. The inferior limit of the maxillectomy is then the floor of the nasal fossa, allowing us the visualisation and control of the alveolar process with the correct endoscope angle.

In a recent article published by the authors analysing 79 patients with primary papillomas, we observed a recurrence rate of 21% that decreased to 18% when malignancy was excluded [10]. According to Krouse's system recurrences in T3 stage were 25%.

In this small review, we have not observed any recurrences.

Conclusions

The technique of endoscopic medial maxillectomy with preservation of inferior turbinate has been successfully used without showing any recurrence and preserving the inferior turbinate function as the main advantage.

References

1. Buchwald C, Franzmann MB, Tos M (1995) Sinonasal papillomas: a report of 82 cases in Copenhagen County, including a longitudinal epidemiological and clinical study. *Laryngoscope* 105(1):72–79
2. Outzen KE, Grøntved A, Jørgensen K, Clausen PP, Ladefoged C (1996) Inverted papilloma: incidence and late results of surgical treatment. *Rhinology* 34(2):114–118
3. Sauter A, Matharu R, Hörmann K, Naim R (2007) Current advances in the basic research and clinical management of sinonasal inverted papilloma (review). *Oncol Rep* 17(3):495–504
4. Llorente JL, Deleyiannis F, Rodrigo JP, Nuñez F, Ablanedo P, Melón S, Suárez C (2003) Minimally invasive treatment of the nasal inverted papilloma. *Am J Rhinol* 17(6):335–341
5. Kraft M, Simmen D, Kaufmann T, Holzmann D (2003) Long-term results of endonasal sinus surgery in sinonasal papillomas. *Laryngoscope* 113(9):1541–1547
6. Tomenzoli D, Castelnuovo P, Pagella F, Berlucchi M, Pianta L, Delù G, Maroldi R, Nicolai P (2004) Different endoscopic surgical strategies in the management of inverted papilloma of the sinonasal tract: experience with 47 patients. *Laryngoscope* 114(2):193–200
7. Von Buchwald C, Larsen AS (2005) Endoscopic surgery of inverted papillomas under image guidance—a prospective study of 42 consecutive cases at a Danish university clinic. *Otolaryngol Head Neck Surg* 132(4):602–607
8. Busquets JM, Hwang PH (2006) Endoscopic resection of sinonasal inverted papilloma: a meta-analysis. *Otolaryngol Head Neck Surg* 134(3):476–482
9. Pasquini E, Sciarretta V, Farneti G, Modugno GC, Ceroni AR (2004) Inverted papilloma: report of 89 cases. *Am J Otolaryngol* 25(3):178–185
10. Gras-Cabrero JR, Montserrat-Gili JR, Masegur-Solench H, León-Vintró X, DeJuan J, Fabra-Llopis JM (2010) Management of sinonasal inverted papillomas and comparison of classification staging systems. *Am J Rhinol Allergy* 24(1):66–69
11. Krouse JH (2000) Development of a staging system for inverted papilloma. *Laryngoscope* 110(6):965–968
12. Cannady SB, Batra PS, Sautter NB, Roh HJ, Citardi MJ (2007) New staging system for sinonasal inverted papilloma in the endoscopic era. *Laryngoscope* 117(7):1283–1287
13. Sham CL, Woo JK, van Hasselt CA (1998) Endoscopic resection of inverted papilloma of the nose and paranasal sinuses. *J Laryngol Otol* 112(8):758–764
14. Sadeghi N, Al-Dhahri S, Manoukian JJ (2003) Transnasal endoscopic medial maxillectomy for inverting papilloma. *Laryngoscope* 113(4):749–753
15. Willatt D (2009) The evidence for reducing inferior turbinates. *Rhinology* 47(3):227–236
16. Garth RJ, Cox HJ, Thomas MR (1995) Haemorrhage as a complication of inferior turbinectomy: a comparison of anterior and radical trimming. *Clin Otolaryngol Allied Sci* 20(3):236–238