

## ORIGINAL ARTICLE

# Endonasal endoscopic scalpel-forceps dacryocystorhinostomy vs endocanalicular diode laser dacryocystorhinostomy

Juan R. Gras-Cabrerizo<sup>1</sup>, Joan R. Montserrat-Gili<sup>1</sup>, Xavier León-Vintró<sup>1</sup>, Montse Lopez-Vilas<sup>1</sup>, Fernando Rodríguez-Álvarez<sup>2</sup>, Sergio Bonafonte-Royo<sup>3</sup>, Abelardo Alegría<sup>4</sup>, Humbert Massegur-Solench<sup>1</sup>

<sup>1</sup>Department of Otolaryngology/Head and Neck Surgery, Universitat Autònoma de Barcelona, Barcelona - Spain

<sup>2</sup>Department of Ophthalmology, Hospital de la Santa Creu i Sant Pau, Universitat Autònoma de Barcelona, Barcelona - Spain

<sup>3</sup>Department of Ophthalmology, Centro de Oftalmología Bonafonte de Barcelona, Barcelona - Spain

<sup>4</sup>Department of Anesthesiology, Centro de Oftalmología Bonafonte de Barcelona, Barcelona - Spain

**PURPOSE.** *To compare the efficacy of endonasal endoscopic dacryocystorhinostomy and endocanalicular diode laser dacryocystorhinostomy.*

**MATERIALS AND METHODS.** *A total of 126 dacryocystorhinostomies were performed in 111 patients with epiphora. In 55% of cases (69/126) we performed an endonasal endoscopic dacryocystorhinostomy and in 45% (57/126) we carried out an endocanalicular dacryocystorhinostomy using diode laser. The mean age at diagnosis was 63 years. The mean age was higher in the endocanalicular group than in the endonasal endoscopic group: 64 versus 62 years. There were 25 men (23%) and 86 women (77%).*

**RESULTS.** *Successful results were achieved in 73% of patients (92/126). In the endonasal endoscopic group, 83% of patients (57/69) were symptom free compared to 62% of patients (35/57) in the laser diode group. A bicanalicular nasal silicone tube was left in place for a mean of 2.32 months in the endoscopic endonasal group and for 2.82 months in the laser diode group ( $p=0.164$ ). Median time of recurrence after removal of the tube was 3.56 months (range 0-9.6); 2.84 months in the laser diode group and 4.87 months in the endonasal endoscopic group ( $p=0.069$ ).*

**CONCLUSIONS.** *The endonasal endoscopic approach achieved better results for nasolacrimal obstruction than the endocanalicular laser diode technique.*

**KEY WORDS.** *Dacryocystorhinostomy, Diode laser, Endonasal endoscopic, Epiphora*

Accepted: April 2, 2012

## INTRODUCTION

Dacryocystorhinostomy (DCR) is a surgical procedure to create a passage from the lacrimal sac to the nasal fossa in cases of lacrimal drainage obstruction. Excellent results have been achieved by both ophthalmologists and otorhinolaryngologists.

Many techniques, both external and endonasal, have been used to expose the lacrimal sac. Ophthalmologists are

more accustomed to the external approach, first described by Toti at the beginning of the 20th century (1), while otorhinolaryngologists generally prefer the endonasal route, as it is a common approach in nasosinus surgery. This latter procedure was initially described by Caldwell in 1893 when he reported the case of a successful intranasal operation. This technique posed many difficulties, as Chandler stated in 1936: "Certainly it is an operation not to be undertaken without a sound knowledge of nasal anatomy and

a certain amount of technical skill in nasal work" (1). This endonasal approach improved considerably with the incorporation of the microscope, as described by Heermann in 1958 and Prades in 1970 (2), and it advanced decisively in 1989 when McDonogh and Meiring (3) described endonasal dacryocystorhinostomy using rigid endoscopes.

More recent advances for this pathology include the introduction of different types of laser for both endonasal and endocanalicular approaches. Results vary according to techniques and the outcome criteria used. External and endonasal approaches without laser provide good results in over 80% of patients in most publications (4, 5). Outcomes using laser, however, are controversial as they differ greatly between studies; while some authors report success rates that are similar to those using external and endonasal techniques, other authors report success rates below 50% (6, 7).

The aim of the present study was to compare 2 techniques, the endonasal endoscopic dacryocystorhinostomy approach and the endocanalicular diode laser dacryocystorhinostomy approach.

## MATERIALS AND METHODS

### *Patient characteristics*

We prospectively revised data from all patients at our center who underwent surgery for nasolacrimal obstruction between 2005 and 2010.

A total of 111 patients were treated for nasolacrimal duct obstruction with epiphora, 96 unilaterally and 15 bilaterally, making a total of 126 DCR procedures. Patients presented associated dacryocystitis in 33% of cases (42/126). Acute dacryocystitis was treated with oral antibiotics (amoxicillin + clavulanate), topical antibiotics (tobramycin), and oral anti-inflammatory agents. In some cases external drainage was performed. Patients with chronic dacryocystitis were treated with topical antibiotics.

A total of 120 cases were primary DCR and 6 patients had been operated previously. In 55% of cases (69/126) we performed an endonasal endoscopic scalpel-forceps dacryocystorhinostomy and in 45% (57/126) we carried out an endocanalicular dacryocystorhinostomy using laser diode (Tab. I). Mean age at diagnosis was 63 years with a range of 22 to 88 years. Mean age was higher in the endocanalicular group than in the endonasal endoscopic group: 64 vs 62

years. There were 25 males (23%) and 86 females (77%).

Patients were evaluated by otorhinolaryngologists and ophthalmologists from the Lacrimal Surgery Committee. Examination included lacrimal irrigation, probing, and endoscopy of the nasal cavity. Dacryocystography was used in only 6% of cases. Dacryocystorhinostomy was indicated if the obstruction was in or distal to the lacrimal sac.

We performed a laser technique for patients who rejected general anesthesia or where the general anesthesia was contraindicated if we observed a favorable surgical anatomic area. We performed endonasal endoscopic scalpel-forceps in the remaining patients.

### *Surgical technique*

In the endonasal endoscopic group, surgery was performed under general anesthesia using 0° or 30° rigid endoscopes. Cottonoids previously soaked in 1% tetracaine and adrenaline were placed in the nasal cavity.

We used a modified version of the technique described by Masegur et al (2) in 2004. It has 5 steps:

- 1) Four incisions are created in the mucosa over the frontal process of the maxilla. A horizontal incision is made anteriorly and superiorly to the attachment of the middle turbinate in the lateral wall. A second horizontal incision is made 0.5 cm under the first. Two vertical incisions are performed, one just above the maxillary line (the suture between the maxillary and lacrimal bone), and another anterior to the first incision. The mucosa between the 2 horizontal incisions is removed and the remaining mucoperiosteal flap is reflected over the inferior turbinate.
- 2) The lacrimal bone is then separated from the maxillary bone using a Montserrat angled scalpel. Next, Smith-Kerrison forceps are placed behind the maxillary line. The maximum amount of bone is removed to expose the lacrimal sac above the insertion of the middle turbinate.
- 3) A vertical incision is made along the lacrimal sac using a phacoemulsification angle scalpel and its medial wall is taken out.
- 4) Silicone tubes are inserted through the superior and inferior canaliculus and tied inside the nasal fossa.
- 5) The flap is replaced over the denuded maxillary bone and the nasal cavity is packed for 24 hours.

In the endocanalicular group we performed surgery under local anesthesia. We used a 980 nm diode laser (Laser Surgical S15 OFT, Equipsa SA) in repetitive pulse mode. Laser settings were power 9W, pulse length 50ms, and pause between pulses 50ms.

The surgical technique is performed in 4 steps:

- 1) We block the supraorbital and infraorbital region with local infiltration (Xylocaine + hyaluronidase) and anesthetize the sphenopalatine region with the same infiltration. Cottonoids soaked with tetracaine and adrenaline 1% are placed in the nasal cavity.
  - 2) The lacrimal punctum is dilated and the superior canaliculus is probed. A laser fiber is then inserted and the lateral nasal wall is transilluminated in the saccus region.
  - 3) Osteotomy is performed by applying laser energy with the laser fiber.
  - 4) Collagen pledgets are placed in the middle meatus.
- For both techniques the operation was considered successful if the patient did not present symptoms. In addition, after the silicone tube was removed we evaluated the width of the ostium by nasal endoscopy. If the ostium was not visible the fluorescein test is used.

### Statistical analysis

Recurrences were computed using the Kaplan-Meier method and curves were compared using the Mantel-Haenszel test (log rank). Endpoints were calculated from the date of tube removal until recurrence. Student t test was used to compare means between groups.

## RESULTS

We obtained a successful result in 73% of patients (92/126). In the endonasal endoscopic group, 83% of patients (57/69) were symptom free but 17% were not (12/69). In the laser diode group, 62% of patients (35/57) were symptom free but 38% were not (22/57) (Tab. I). In 87% of patients without epiphora the endoscopy showed a well healed and wide ostium. In the remaining 13% of patients, the ostium was not visible even though patients were asymptomatic, 9 cases in the endonasal endoscopic group and 3 cases in the laser group. Eighty-five percent of patients with epiphora did not have an evident ostium, but 15% of these symptomatic patients had a clear ostium with positive fluorescein test results, 3 cases in the endonasal endoscopic group and 2 cases in the laser group (Tab. II).

Actuarial recurrence-free survival at 1 year was 72% (95% confidence interval [CI] 58-86) for the endonasal endoscopic group and 55% for the endocanalicular laser diode group (95% CI 40-70) ( $p=0.012$ ) (Fig. 1).

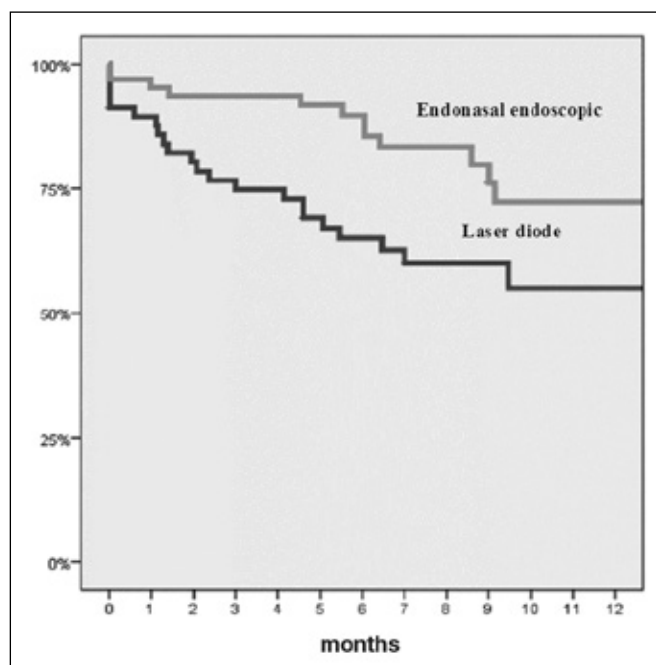


Fig. 1 - Actuarial survival free of recurrence ( $p=0.012$ ).

TABLE I - SYMPTOMATIC RESULTS

Surgery	Epiphora, n (%)	No epiphora, n (%)	Total
Endonasal endoscopy	12 (17)	57 (83)	69
Diode laser	22 (38)	35 (62)	57
Total	34 (27)	92 (73)	126

TABLE II - ANATOMIC AND FUNCTIONAL SUCCESS IN TOTAL POPULATION

	No epiphora, n (%)	Epiphora, n (%)	Total
Visible ostium	80 (87)	5 (15)	85
No visible ostium	12 (13)	29 (85)	41
Total	92	34	126

In all cases bicanalicular silicone tubes were used for lacrimal intubation. We removed the silicone stent at a minimum of 1 month after surgery. The median time was 2.56 months (range 0.53-16.8). In 7 patients, the period with the tube in

**TABLE III - DACRYOCYSTORHINOSTOMY COMPLICATIONS**

	Endonasal endoscopy (n=69)	Laser (n=57)	Total (n=126)
Synechia	9	10	19
Extrusion	3	4	7
Granulations	6	0	6
Hematoma	1	1	2
Epistaxis	0	0	0

place was less than 1 month due to accidental removal. The tube remained in place in the endoscopic endonasal group for an average of 2.32 months and for 2.82 months in the laser diode group ( $p=0.164$ ). Median follow-up from the date of tube removal until follow-up visit was 8 months, with a range of 3 to 52 months.

The median time of recurrence after removal of the silicone tube was 3.56 months (range 0-9.60). Seventy-nine percent of failures (27/34) recurred within the first 6 months (Fig. 1). In the laser diode group the median time of recurrence was 2.84 months as compared to 4.87 months for the endonasal endoscopic group ( $p=0.069$ ). Complications are shown in Table III. The most frequent complication was synechia between the lateral nasal wall and the middle turbinate, seen in 19 cases (15%). Tube extrusion was observed in 7 cases (6%). Five of the patients with accidental prolapse presented recurrence. No major complications were found.

## DISCUSSION

Many studies have been conducted to compare the effectiveness of DCR techniques. It is difficult, however, to compare the outcomes because there is no standardized classification of success, and patient selection and exact surgical techniques vary greatly from one study to another. Whatever the technique used, however, surgical success is related to the size of the ostium after the lacrimal sac is opened. To achieve as wide an ostium as possible, it is important to remember some specific anatomic aspects of the lacrimal fossa and lacrimal sac:

1. The posterior surface of the lacrimal sac is covered by the unguis. To identify the entire lacrimal sac it is necessary to remove not only the frontal process of the maxillary bone but also the lacrimal bone.

2. As described by Wormald et al (8), two-thirds of the sac are above the insertion of the middle turbinate on the lateral nasal wall. It is key to surgery to remove the thick bone above the attachment of the middle turbinate. If we identify the orifice of the common canaliculum inside the sac, we can be sure that we will expose the superior part of the sac.

3. Although several authors recommend removing the uncinat process to gain access to the lacrimal sac (9, 10), we do not consider this necessary because the lacrimal fossa is covered by the uncinat only in its superior attachment. Superior insertion is found, in most cases, above the common canaliculum. We only recommend this procedure if the uncinat process is prominent and blocks the medium meatus. Outcomes using the endonasal endoscopic approach have good long-term results. Published results range from 83% to 94% and are comparable with results for the external procedure (4). We observed similar results; 83% of patients did not present symptoms. Outcomes with the diode laser technique are a matter for discussion (4). In our population only 62% of the patients operated with diode laser did not report epiphora. Recurrences in the laser population were therefore twice those in the endonasal endoscopic group. This outcome is poorer than the results in many endocanalicular laser publications. Ajalloueyan et al (7) obtained over a 90% success rate in both the external and endocanalicular laser procedures, in 244 operated eyes. Özçimen et al (11) reported that 83% of patients who underwent endocanalicular laser diode did not report symptoms. Drnovsek-Olup et al (12) found a similar average in a larger population. Maeso Riera et al (13) found clinical improvement in 142 of 150 eyes treated with transcanalicular approach and laser diode and Alañón Fernandez et al (14) had equivalent outcomes, more than 90%, in a similar population, with a follow-up of 15 months.

We did not achieve these excellent outcomes with laser diode and we consider this is likely related to the characteristics of the osteotomy. The most common causes of unsuccessful DCR surgery are inappropriate bone ostium size and inaccurate localization (15). The neo-ostium created using the endocanalicular technique is smaller, lower, and more posterior than the osteotomy created with the non-laser approach. Argin et al (16) recommend a bone size defect of 2 × 2 centimeters to prevent restenosis. In our experience, achieving this size is not feasible with the laser fiber alone. Trying to enlarge the neo-ostium after an osteotomy has been created using laser is not easy as this type of surgery is performed under local anesthesia, more-

over, such manipulation usually creates more trauma in surrounding tissues, particularly synechiae with the middle turbinate. In the endonasal endoscopic approach it is possible to obtain a large rhinostomy because we remove as much maxillary bone as possible using Smith Kerrison forceps. We always remove the bone above the axilla of the middle turbinate to identify the common canaliculum. Currently we prefer to perform the whole DCR process using the endoscopic endonasal approach, reserving the laser technique for patients in whom general anesthesia is contraindicated, or for patients who refuse general anesthesia. The most important factor to reach a successful outcome in the laser group is to operate within a favorable surgical anatomic area. Visibility of the axilla of the middle turbinate, the maxillary line, and a free middle meatus is essential to obtain good results. We should be aware that it is not possible to create an ostium with laser and local anesthesia that is as large as that obtained with other techniques. Most studies use silicone tubes (4) but there are few publications that compare groups with and without stenting. In their series of 86 eyes operated with endonasal laser, Sadiq et al (17) observed a 33% failure rate at 3 months in the group without intubation compared to 18% in the group with intubation. On the other hand, however, Smirnov et al (18) showed that silicone tubes after primary endonasal DCR were not necessary and that results were better in the group without tubes (100% vs 78%). We always use bicanalicular silicone tubes and in the present study they remained in place for at least 1 month. Premature extrusion was not associated with an increase in surgical failure in some populations (4) but 71% of patients with accidental prolapse in our study presented recurrence. We consider that leaving a silicone tube in place may facilitate continuous fluid flow by maintaining a wide neo-ostium.

We found that more than 70% of failures recurred within the first 6 months. In the laser diode group the median time to recurrence was approximately 2 months shorter than in the endonasal endoscopic group. For recurrence to occur it is logical that a smaller osteotomy would close before a larger one. Taking our outcomes into account we recommend follow-up in patients until at least 6 months after removing the silicone tube.

In 87% of patients who did not present epiphora in the postoperative follow-up, we obtained an anatomic success. The nasal endoscopy showed a well-healed, wide ostium. The ostium was not visible, however, in 13% of these patients. Some patients suffered from synechiae and

the ostium was not visible. In other cases the ostium was more posterior or it was minimal and not visible in spite of being functional.

Eighty-five percent of patients with epiphora did not have an evident ostium in the lateral nasal wall and closure of the ostium would explain the recurrence. But 15% of these symptomatic patients had a clear ostium with a positive fluorescein test. This means an anatomic success but a poor functional outcome. There are probably 2 events that could explain this result. First, there may be canalicular pathology with saccal obstruction, in which case opening at the level of the lacrimal sac to bypass the obstruction of the nasolacrimal duct could be insufficient. O'Donnell et al (19) showed that lacrimal syringing or fluorescein dye test alone were not predictive of surgical outcome and they suggested that canalicular pathology can be underdiagnosed. Second, epiphora could be caused by a physiologic dysfunction such as lacrimal pump failure due to lower lid laxity, weakness of the orbicular muscle, or punctal eversion. It is essential to distinguish epiphora caused by mechanical obstruction from that due to a physiologic process; besides, both pathologies may be present in the same patient.

We did not find major complications in either group. Synechiae between the lateral wall and the middle turbinate was the most frequent complication, seen in 19 cases (15%). We observed 18% of synechiae in the laser diode group and 13% in the endonasal endoscopic group. The greater occurrence in the former group could perhaps be related to the difficulty in displacing or removing the head of the middle turbinate during surgery to prevent this.

Tube extrusion was observed in 7 cases (6%): 3 in the endoscopic group and 4 in the laser diode group. In our population this extrusion was a poor prognostic factor.

## CONCLUSIONS

We obtained better results in patients who underwent surgery for nasolacrimal obstruction using the endonasal endoscopic approach than in those who were operated by the endocanalicular laser diode technique. Recurrences were twice as high in the laser diode group.

*The authors report no proprietary interest or financial support.*

Address for correspondence:

Juan R. Gras-Cabrerizo, MD  
Department of Otolaryngology/Head and Neck Surgery  
Hospital de la Santa Creu i Sant Pau  
Universitat Autònoma de Barcelona  
Mas Casanova 90  
Barcelona 08019, Spain  
jgras@santpau.cat

---

## REFERENCES

1. Chandler PA. Dacryocystorhinostomy. *Trans Am Ophthalmol Soc* 1936; 34: 240-63.
2. Massegur H, Trias E, Ademà JM. Endoscopic dacryocystorhinostomy: modified technique. *Otolaryngol Head Neck Surg* 2004; 130: 39-46.
3. McDonogh M, Meiring JH. Endoscopic transnasal dacryocystorhinostomy. *J Laryngol Otol* 1989; 103: 585-7.
4. Leong SC, Macewen CJ, White PS. A systematic review of outcomes after dacryocystorhinostomy in adults. *Am J Rhinol Allergy* 2010; 24: 81-90.
5. Lee DW, Chai CH, Loon SC. Primary external dacryocystorhinostomy versus primary endonasal dacryocystorhinostomy: a review. *Clin Experiment Ophthalmol* 2010; 38: 418-26.
6. Patel BC, Phillips B, McLeish WM, Flaharty P, Anderson RL. Transcanalicular neodymium: YAG laser for revision of dacryocystorhinostomy. *Ophthalmology* 1997; 104: 1191-7.
7. Ajalloueyan M, Fartookzadeh M, Parhizgar H. Use of laser for dacryocystorhinostomy. *Arch Otolaryngol Head Neck Surg* 2007; 133: 340-3.
8. Wormald PJ, Kew J, Van Hasselt A. Intranasal anatomy of the nasolacrimal sac in endoscopic dacryocystorhinostomy. *Otolaryngol Head Neck Surg* 2000; 123: 307-10.
9. Soyka MB, Treumann T, Schlegel CT. The Agger Nasi cell and uncinat process, the keys to proper access to the nasolacrimal drainage system. *Rhinology* 2010; 48: 364-7.
10. Fayet B, Racy E, Assouline M. Systematic uncinectomy for a standardized endonasal dacryocystorhinostomy. *Ophthalmology* 2002; 109: 530-6.
11. Özçimen M, Uysal IO, Eryılmaz MA, Kal A. Endocanalicular diode laser dacryocystorhinostomy for nasolacrimal duct obstruction: short-term results of a new minimally invasive surgical technique. *J Craniofac Surg* 2010; 21: 1932-4.
12. Drnovsek-Olup B, Beltram M. Transcanalicular diode laser-assisted dacryocystorhinostomy. *Indian J Ophthalmol* 2010; 58: 213-7.
13. Maeso Riera J, Sellarès Fabrès MT, eds. Transcanalicular diode laser dacryocystorhinostomy: technical variations and results. *Acta Otorrinolaringol Esp* 2007; 58: 10-5.
14. Alañón Fernández MA, Alañón Fernández FJ, Martínez Fernández A, Cárdenas Lara M. [Results of the application of mitomycin during endonasal and endocanalicular dacryocystorhinostomy by diode laser.] *Acta Otorrinolaringol Esp* 2006; 57: 355-8.
15. Konuk O, Kurtulmusoglu M, Knatova Z, Unal M. Unsuccessful lacrimal surgery: causative factors and results of surgical management in a tertiary referral center. *Ophthalmologica* 2010; 224: 361-6.
16. Argin A, Görür K, Ozcan C, Arslan E, Ozmen C, Vayisoglu Y. The role of larger osteotomy in long term success in external dacryocystorhinostomy. *J Plast Reconstr Aesthet Surg* 2008; 61: 615-9.
17. Sadiq SA, Ohrlich S, Jones NS, Downes RN. Endonasal laser dacryocystorhinostomy—medium term results. *Br J Ophthalmol* 1997; 81: 1089-92.
18. Smirnov G, Tuomilehto H, Teräsvirta M, Nuutinen J, Seppä J. Silicone tubing is not necessary after primary endoscopic dacryocystorhinostomy: a prospective randomized study. *Am J Rhinol* 2008; 22: 214-7.
19. O'Donnell BA, Clement CI. Assessing patients with epiphora who are patent to syringing: clinical predictors of response to dacryocystorhinostomy. *Ophthal Plast Reconstr Surg* 2007; 23: 173-8.